

Retinopathy of Prematurity

GGW Adams

Moorfields Eye Hospital, London

Financial Interests

- No financial interests to declare

ROP overview

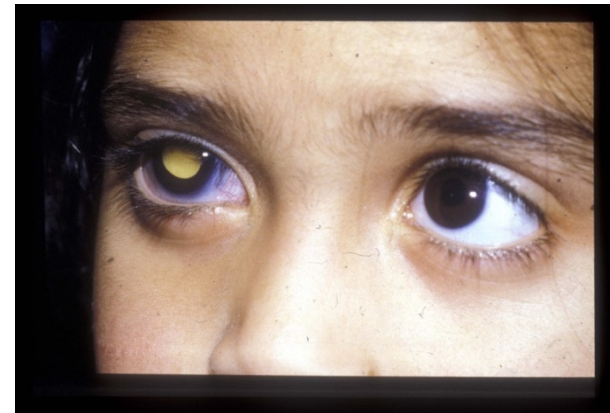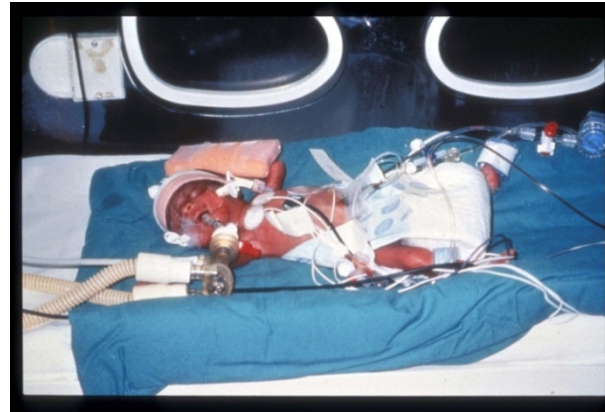- Definitions
- UK/worldwide perspective
- Retinal vascular development
- Current practice
- New developments : anti-VEGF

Definitions

- Preterm: born before 37 weeks gestation
- Extremely preterm: born before 28 weeks gestation
- About 6-8% of deliveries are preterm
- 1.5% of babies are born before 32 weeks
- 0.4 per cent of babies are born before 28 weeks
- Birth rate in UK 765,294 in 2009
- Of these, 58,875 babies were born prematurely

Retinopathy of prematurity

- Neovascular retinal disorder of premature babies
- ROP now mainly a disease of micro prem babies <800g, <26 weeks
- Potentially blinding disease
- Most ROP is mild/moderate and regresses
- Severe ROP can result in retinal detachment



Blindness from ROP

- 50,000 children blind world wide from ROP
- ROP accounted for 3% UK childhood blindness in 2000
- ROP causes 60% of childhood blindness in Argentina, > 50% in Poland, Russia
- Every 2hrs 3 babies in India reach threshold

Normal retinal vascularisation

- Choroid vascularises at 6 weeks
- Retinal vascularisation starts at optic nerve head at 16 weeks gestation
- Proceeds outward to the periphery
- Vascularisation is almost complete by term
- Vasculogenesis: primitive plexus formed from precursor cells, not VEGF dependant
- Angiogenesis: new vessels from pre existing vasculature, VEGF dependant
- Central 1/3 formed by vasculogenesis

Pathogenesis of ROP

Premature delivery interrupts normal vascular growth

Phase 1 : delayed retinal vascularisation (birth-31/32 weeks)

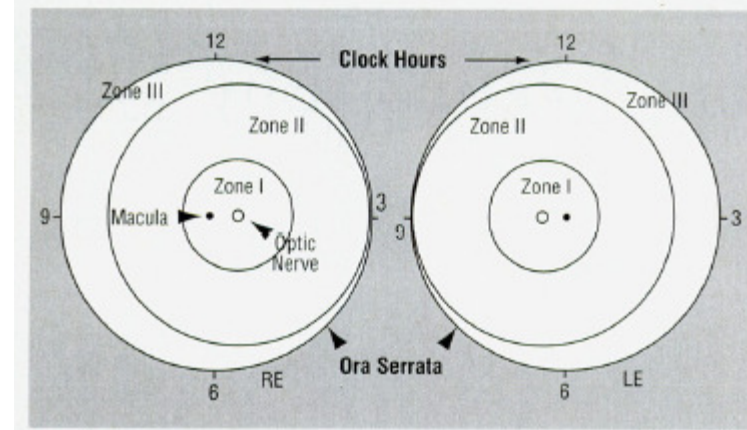
- Developing retina exposed to hyperoxic environment (ambient and supplemental)
- Reduces angiogenic factors delaying retinal vascularisation

Phase 2 : neovascularisation

- Neuroretina continues to develop causing hypoxia with overproduction of angiogenic factors especially VEGF
- Causes uncontrolled retinal blood vessel growth

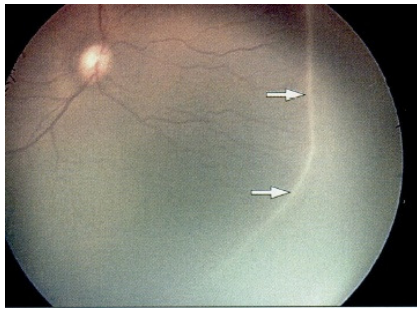
Classification

- International classification 2005
- Location
- Severity
- Extent in clock hours
- Presence of plus/pre plus disease
- Stage 1/2 mild
- Stages 3 - 5 severe
- Stages 4b and 5 damage sight

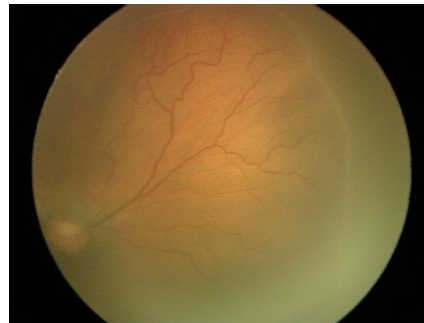


ROP stages

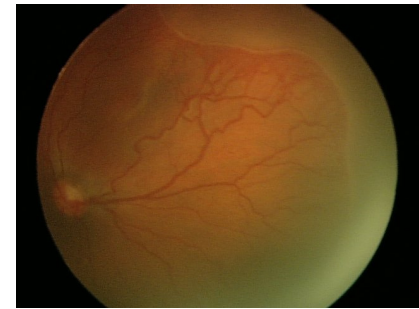
Stage 1



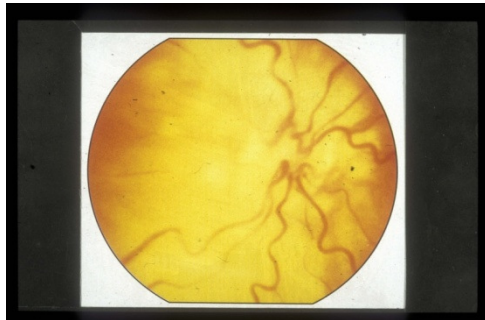Stage 2



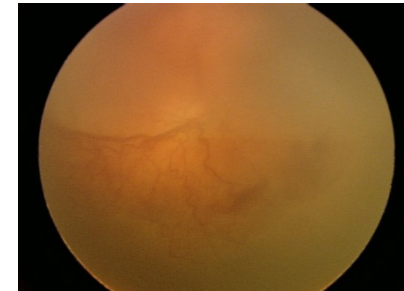
Stage 3



Stage 4

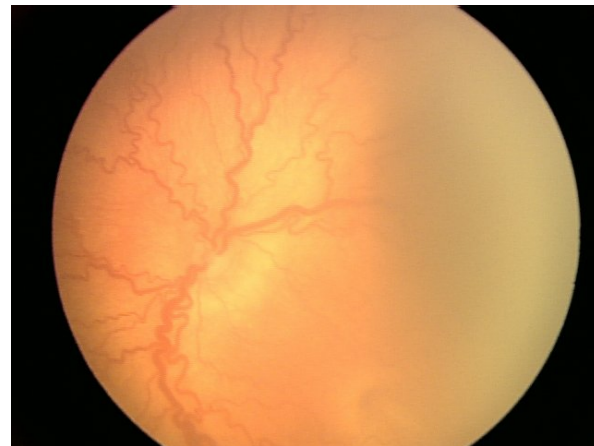
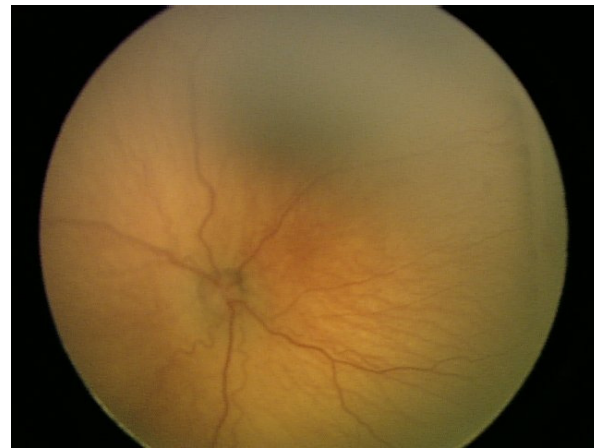


AP-ROP



Natural history of ROP

- 8 week period of disease
- Most ROP develops 30 - 40 weeks
- Most stage 3 develops 34 - 42 weeks



Treatment of ROP

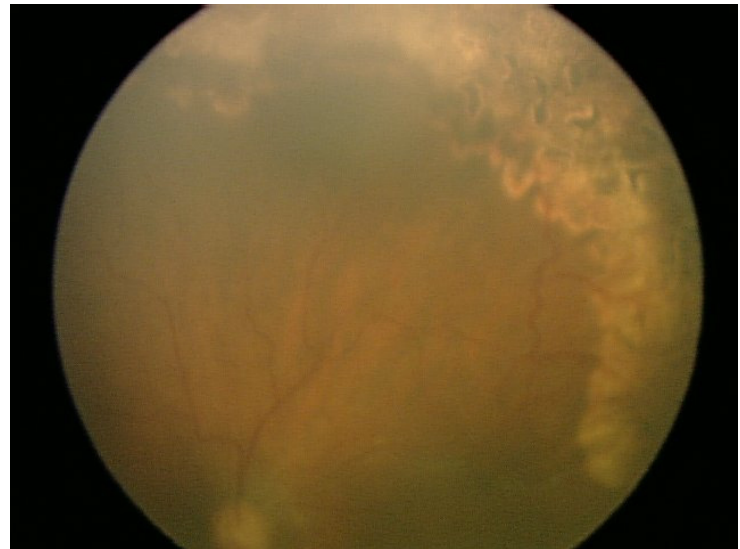- 1988 CryoRop study published
- Treatment at threshold (50% chance of blindness)
- 15 year outcomes continue to show long-term benefit
- 10 years after treatment 44.4% had acuity of $\leq 20/200$
- Now moved to earlier treatment, mostly with laser
- Better structural and functional outcomes
- More babies need treatment

UK screening/treatment guidelines

- Screen all babies up to 31+6
- Screen all babies <1501g
- Start screening at 31 or 4-5 weeks post birth
- Screen 1 to 2 weekly
- Treatment within 48 hours should be a target standard
- >8,000 babies screened yearly

Laser treatment

- 229 babies treated in 2007
- 30 treating doctors
- 50% of babies treated under general anaesthetic
- 37% treated with IV sedation
- High success rate
- Requires equipment, expertise, staff
- Peripheral scarring



New treatment for ROP?

- Training required for laser
- Significant use of other staff: neonatal, anaesthetic
- Expensive infrastructure
- Field defect from retinal scarring
- Avastin is cheap and treatment quick

Anti-VEGF agents in ophthalmology

- Macugen (pegaptanib sodium)
- Avastin (bevacizumab)
- Lucentis (ranibizumab)
- Aflibercept (VEGF Trap)

Anti-VEGF use in ophthalmology

- Age-related macular degeneration
- Central and branch retinal vein occlusion
- Diabetic retinopathy
- Neovascular glaucoma
- Corneal neovascularisation
- Choroidal neovascularisation
- Coats, von Hippel Lindau, FEVR

Ocular complications with anti-VEGF

- Infection: endophthalmitis
- Raised intraocular pressure
- Cataract
- Retinal detachment
- Central retinal artery occlusion
- Vitreoretinal fibrosis
- Corneal abrasion
- Uveitis
- Acute vision loss
- Subretinal haemorrhage
- Retinal pigment epithelial tears

Reported systemic effects in adults

- Blood pressure elevation
- Transient ischaemic attack
- Cerebrovascular accident and death
- More systemic side-effects reported with Avastin

Paediatric uses for anti-VEGF

- Coats disease: case reports
- Choroidal neovascular membranes: case reports
- FEVR: case reports
- ROP: prospective, controlled randomised trial

BEAT-ROP study

- Bevacizumab Eliminates the Angiogenic Threat of Retinopathy Of Prematurity
- Prospective, randomized, US multicentre, controlled clinical trial
- Compared intravitreal Avastin 0.625mg (0.025ml) as primary therapy with conventional laser therapy for stage 3+ ROP
- 150 infants (300 eyes);
- 7 died and not included in data (5 in Avastin group, 2 in laser)
- 67 had zone 1 ROP
- 83 had zone 2 posterior ROP
- 75 in each treatment group
- Higher rate of recurrence for zone 1 disease with laser
- 2 cases (eyes) of recurrence with Avastin, 23 with laser
- Significant effect for zone 1 disease, not for zone 2 disease

BEAT-ROP study

- Avastin significant effect for zone 1 disease, not for zone 2 disease
- Efficacy shown, safety not proved
- Later recurrence after Avastin: 16 ± 4.6 weeks, laser 6.2 ± 5.7 weeks
- Avastin treated babies need longer follow-up

Issues

- High failure rate with laser, higher than for UK
- Underpowered - would need 2,800 infants to establish systemic safety
- Follow-up longer/more problematic than laser
- The main question is not efficacy but safety

Safety concerns

- Intravitreal Avastin enters the general circulation, suppresses plasma VEGF levels and remains in the blood for more than 8 weeks in primates.
- Possible adverse effects on VEGF-dependent development must be considered.

(normal angiogenesis, regulation of vascular permeability, endothelial differentiation during fetal brain development, signalling between major neural cells, maintenance and development of the blood–brain barrier)

Evidence for systemic absorption

- 11 infants with ROP
- Mean gestation of 25 weeks
- All had undergone laser
- 0.25 mg or 0.5 mg of bevacizumab by intravitreal injection
- Serum samples of bevacizumab and VEGF collected before treatment and 1 day, 1 week, and 2 weeks after treatment
- There was a significant negative correlation between the serum concentration of bevacizumab and VEGF
- “These results indicate that bevacizumab can escape from the eye into the systemic circulation and reduce the serum level of VEGF in infants with ROP. Continued extensive evaluations of infants are warranted for possible effects after intravitreal bevacizumab in ROP patients.”

Other ROP anecdotal reports

- Pulmonary hypertension developing after Avastin injections
- 5/7 deaths in BEAT-ROP were in the Avastin group from respiratory disease

The future

- Could anti-VEGF therapy replace laser therapy?
- Would reduce many difficulties currently associated with treatment
- Would have a huge impact worldwide
- Currently 0.625mg to each eye - half adult dose
- We need long-term evaluation to look for possible systemic side-effects

Where now

- UK trial
- We need underlying data
- What dosage of Avastin do we use?
- Are developmental problems the result of prematurity or treatment?
- Photo documentation/fluorescein angiogram?

Summary

- ROP remains a worldwide potentially blinding problem
- CryoRop showed the benefit of treatment
- Laser now the current standard treatment
- Issues of service delivery
- Anti-VEGF shows promise, particularly for zone 1 disease
- Safety of anti-VEGF needs to be demonstrated